



Spider bite and its treatment in southern Africa

Dr C. Snyman,
MB ChB, DGG, DOH,
DHSM,
Occupational Medicine
Practitioner (Private
Practice),
e-mail:
chrisrs@intekom.co.za

Mr. N. Larsen,
Volunteer
Arachnologist,
Iziko SA Museum,
Cape Town
e-mail:
ndlarsen@netactive.co.za

*Little Miss Muffet sat on her tuffet
Eating her curds and whey
When down came a spider and sat down beside
her
And frightened Miss Muffet away
(Old English nursery rhyme)*

A phenomenon of human behaviour is mortal fear of small creatures with many legs. In many cases, these creatures could comfortably fit on a thumb-nail; but for the fact that the human wouldn't let them near enough to try out any nail. Perhaps the reason for this fear lies in the occasionally fatal nature of the bite of a minority of some classes of these creatures.

The few medically important spiders of South Africa are discussed in this article.

NEUROTOXIC SPIDERS

Button spiders

Also known as widow spiders, *Latrodectus indistinctus* (black button spider) (Figure 1) and *L. geometricus* (brown button spider) (Figure 2) have neurotoxic venom. Previously *L. indistinctus* was known as *L. mactans*; but spiders from different continents shared this name and were found to be distinctly genetically different¹. *Latrodectus indistinctus* has since been further divided into four species: 1) *L. indistinctus*: Western Cape Province northwards to Swakopmund in Namibia. 2) *L. cinctus*: coastal Western Cape Province eastwards to KwaZulu-Natal and northwards to Zimbabwe. 3) *L. karooensis*: Karoo. 4) *L. renivulvatus*: Eastern Cape Province north through Free State to Zimbabwe and the northern parts of Botswana and Namibia⁹. A further species, *L. rhodesiensis*, occurs from Gauteng northwards into Zimbabwe⁹.

The female *L. indistinctus* group body length is 7–15,6 mm (excluding legs). Her abdomen is spherical, and black or dark brown. The dorsal side of the abdomen is decorated with clear red stripes that reduce with each moult until only a red dot is visible above the spinnerets. This red



FIGURE 1. BLACK BUTTON SPIDER (*LATRODECTUS INDISTINCTUS*).



FIGURE 2. BROWN BUTTON SPIDER (*LATRODECTUS GEOMETRICUS*).

dot may even be absent in adult spiders (Figure 1). The legs are long and thin, with the third pair characteristically shorter than the rest. She spins an irregular web between grass or stones. The male spider is small, with abdomen only 2,6–4,85 mm long.

This spider occurs most commonly in the veld^{6,9}. Its bite mark is often unremarkable.

L. geometricus (Figure 2) and *L. rhodesiensis* are slightly smaller than (8–13,9 mm), but of the same build as the black button spider. The body varies from cream to brown to almost black. The dorsal abdomen has yellow to orange geometric markings, which radiate down the sides of the abdomen (Figure 3). The ventral abdomen

This article was first published in *Shell Health Digest*, second quarter 2004. (A publication of Shell International Health Services.) It was revised for *Occupational Health SA* and is re-published by kind permission of Dr Peter Boogaard, editor of *Shell Health Digest*.



FIGURE 3.
BROWN BUTTON SPIDER (*LATRODECTUS GEOMETRICUS*) –
DORSAL VIEW.



FIGURE 4. BROWN BUTTON SPIDER (*LATRODECTUS
GEOMETRICUS*) – VENTRAL ABDOMEN.

displays a characteristic orange-red hour-glass marking (Figure 4). This spider is widely distributed in South Africa, occurring mainly in urban environments; specifically around homes. The web is found under window sills, drain pipes, garden furniture, post boxes and outside toilets.^{6,7}

L. geometricus and *L. rhodesiensis* are differentiated by the egg case, *L. geometricus* having a round egg case with spicules. *L. rhodesiensis*' egg case is 2,5 times larger than that of *L. geometricus* and is round and smooth.

The features of brown button spider envenomation are similar to those of the black button spider, but less severe.

The venom of *Latrodectus* species contains a protein neurotoxin known as α -latrotoxin, which binds with high affinity to a specific presynaptic receptor, setting in motion a massive release of neurotransmitters, mainly acetylcholine and noradrenaline.⁷

Clinical features of envenomation are:

- Burning pain at the bite site; the pain typically spreads to the regional lymph nodes within 15 minutes. These lymph nodes become tender and palpable.
- Within an hour there is generalized muscle pain and cramps, especially of large muscle groups. There may be a feeling of tightness in the chest as well as tremors and weakness when walking.
- Profuse sweating; the clothing and bedding may be soaked.
- A painful facial grimace; with facial oedema.
- Fever, nausea, vomiting, headache and lacrimation, hypertension, tachycardia OR bradycardia; and speech disturbances.

There are no investigations of value in establishing the diagnosis^{2,7}.

Treatment of latrodectism^{2,7}:

- Patients with neurotoxic symptoms require hospitalization and monitoring of vital signs for at least 24 hours.
- Systemic signs and symptoms should be treated with *Latrodectus* spider antivenom (obtainable from the South African Vaccine Producers (Pty) Ltd, tel: (011) 386 6000). One 5 ml ampoule should be given intramuscularly; or diluted in 50 ml saline and given intravenously over 15 minutes. The dose is identical for adults and children. Precautions against anaphylaxis must be taken. (In Müller's series of 45 cases studied, 29 were given antivenom and there were no adverse reactions⁷.)
- 10 ml of a 10% calcium gluconate solution intravenously may give transient relief from cramps.
- Intravenous fluid should be administered to keep the patient hydrated.
- The bite should be topically cleansed, but no bandage or injection or other interference applied.
- Opioids should be avoided.
- Tetanus toxoid should be administered.
- Patients should be kept under observation for 12 hours after cessation of treatment.

Differential diagnosis includes acute abdomen (the abdomen, although rigid, is non-tender in latrodectism), scorpionism, snakebite, alcohol withdrawal, organophosphate poisoning and myocardial infarction⁷.

Of note is that mortality from latrodectism is low – less than 5%¹³ of untreated cases in pre-1960, and no known deaths in the last 4–5 decades^{9,18}.



FIGURE 5. SAC SPIDER (*CHEIRACANTHIUM FURCULATUM*).

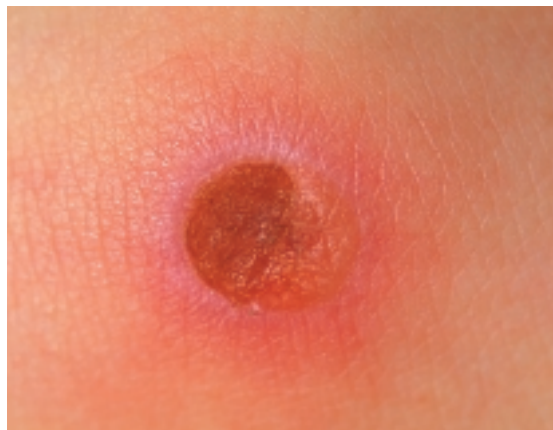

FIGURE 6. SAC SPIDER (*CHEIRACANTHIUM*) BITE.



FIGURE 7. VIOLIN SPIDER (*LOXOSCELES*).

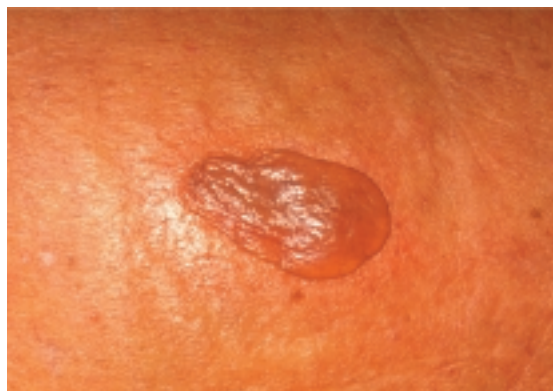

FIGURE 8A. VIOLIN SPIDER BITE AT 72 HOURS.

CYTOTOXIC SPIDERS

There are three important spiders in this group.

Cheiracanthium (sac spiders) and Loxosceles (violin spiders) are widely distributed in South Africa. A further cytotoxic spider is Sicarius (six-eyed sand spider).

Sac spiders are straw-coloured. The abdomen may be tinged greenish with large, shiny, black mouth parts (Figure 5). *Cheiracanthium furculatum*¹⁰ is nocturnal, fast-moving and often found in houses, between folds of curtains and clothing. Its presence may be noticed by its silk retreat in the cornices of houses.

The bite is irregular with a central haemorrhagic vesicle or pustule (bulls-eye lesion). It is not very painful. The bite marks are often visible on the first day as two yellow to green spots (representing the injected subcutaneous venom) 4–8 mm apart^{5,12,13} (Figure 6). There may be extensive erythema, regional lymphadenitis, scarlatiniform rash and a transient fever.

Of the violin spiders, *Loxosceles parrami* is of importance, as it is found in human habitations in the Gauteng area. Other species are of equal clinical importance. It is 6–10 mm long (excluding legs) with long slender legs (Figure 5). It has a characteristic dark-brown to black violin-shaped marking on the carapace. It is not web-bound.

Most bites occur while the victim is asleep. Pain may be absent, or occur only after several hours. An oedematous red lesion with a dusky centre occurs two hours after the bite. It becomes swollen, often vesicular or bullous. It leaves an ulcerated wound penetrating the entire depth of the dermis (Figure 8a, 8b, 8c).

Differential diagnosis includes cellulitis, necrotizing anaerobic fasciitis, insect stings or bites and tick-bite fever.

Treatment of sac and violin spider bites is directed at preventing or limiting secondary infection and promoting healing⁸. Sac spider bites may progress to cellulitis which requires systemic antibiotics. The sac spider bite limits itself after 10 days. Violin spider bites may require surgical debridement and even skin grafts^{2,4}. Two references^{3,4} mention hydrocortisone treatment but this has proved to be inconclusive¹².

No antivenom is available.

These bites require tetanus toxoid booster.

Sicarius is an 8–15 mm spider (excluding

legs). The body is broad and depressed with its latigrade legs spanning up to 50 mm. The leathery cuticle has curved bristles which trap sand particles rendering its yellow to maroon body the same colour to that of the sand in which it occurs (Figure 9). Bites by *Sicarius* are uncommon; there are no proven cases of *Sicarius* bites and only two suspected cases where the culprit was never identified.

Experiments done on rabbits^{13,15,17,19} suggest that *Sicarius* bites are lethal. The experimental bites resulted in purple discoloured weals that developed into 50–100 mm lesions with the 20–30 mm black, necrotic central zone disintegrating, when touched, after 6 hours. The rabbits died 5–12 hours after being bitten.

Autopsies revealed extensive subdermal tissue damage and petechial haemorrhages in the liver, heart and lungs. Death was by respiratory failure. Biochemical evidence of disseminated intravascular coagulopathy (DIC) developed in the rabbits.

Sicarius bite treatment should be directed, as with all cytotoxic bites, at prevention of secondary infection and combating DIC if it develops^{13,15,16,19}.

OCCUPATIONS AT RISK OF SPIDER BITE

Of Müller's 1993 series⁷, half the black widow bites occurred in the home environment (inside and outside), the other half in the veld. The bites in the home are possible translocation in clothing or firewood as no webs were found. Of the latter half, 9 (of 15) were associated with farming activities. Most brown widow bites occurred in or around the house. One occurred in a vineyard. All cases studied in this series were bitten in the Western Cape, *L. indistictus* being responsible.

Considering descriptions of distribution and occurrence from the reference list^{1,3,4,6,7,8}, one can surmise that risk of spider bite exists in worker populations as per Table 1.

OTHER SPIDERS

One other type of spider warrants mention, if only for its potential to strike terror into Miss Muffet's heart. (And that of many a home executive and mother, in the authors' experience!)

The rain spider, *Palystes superciliosus* (formerly *P. natalius*) is an impressive creature (Figure 10). The body is brownish-grey, and up

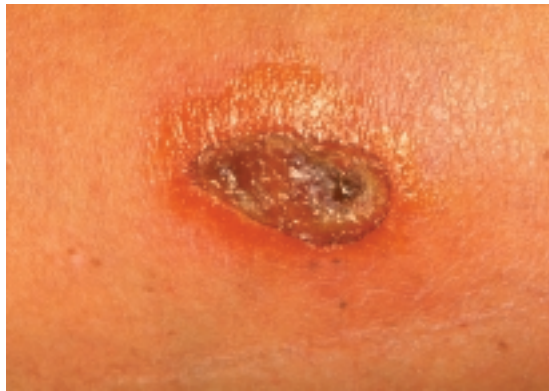


FIGURE 8B. VIOLIN SPIDER BITE AT 4 WEEKS.

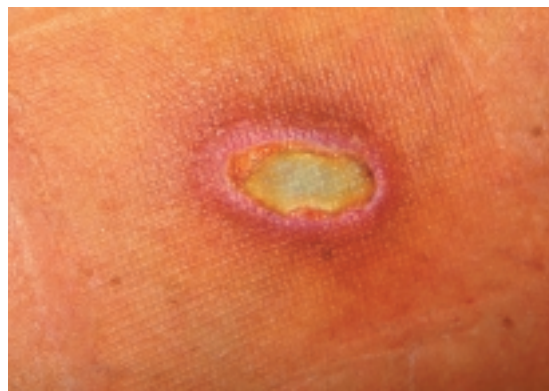

FIGURE 8C. VIOLIN SPIDER BITE HEALING.



FIGURE 9. SIX-EYED SAND SPIDER (*SICARIUS*).



FIGURE 10. RAIN SPIDER (*PALYSTES SUPERCILIOSUS*).

TABLE 1.

Black widow spider bites	Brown widow spider bites; sac and violin spider bites
Construction workers – new sites in rural areas	Construction workers in urban areas
Agricultural workers	Builders and painters renovating existing homes
Municipal and utility workers clearing servitudes under overhead cables and in city suburbs	Domestic workers (common risk factor)
Domestic workers (rare risk factor)	Entomologists
Entomologists	

to 30 mm long in the female. The ventral surfaces of the legs are bright yellow with transverse black bands and has a distinctive clypeal (area between eyes and anterior edge of carapace) moustache. These spiders are commonly found in human habitations¹¹.

In 1959 Steyn allowed a *P. superciliosus* to bite an adult guinea pig on the nose. The guinea pig died within 7 minutes. The fearsome reputation of this spider remains, despite subsequent research on anaesthetized guinea pigs showing that the first experiment resulted in death by shock due to fright. (Apparently this is something to which guinea pigs are prone!)⁵

The bite causes a burning sensation, and may result in swelling which lasts a few days. Recovery is spontaneous and complete.

PERSPECTIVE

In a study done by Russell and Gertsh of 600 suspected spider bites, 80% were found to be caused by fleas, bed bugs, ticks etc and a significant percentage of the rest were the result of skin manifestations and other diseases¹⁴.

IN SUMMARY

- The button spiders and the Sicarius are the only potentially fatal type of South African spider.
- Cytotoxic spider bites require careful wound treatment; other South African spider types are not medically important.
- Certain occupations are at increased risk of spider bite.
- Miss Muffet is a mythical figure and her example need not be followed.

REFERENCES

1. Martindale, C.B. and Newlands, G. The widow spiders: a complex of species. *SA Journal of Science*, Vol 78, Feb 1982, pp 78–79.

2. Leonard Schriro, Gert J. Müller, Liron Pantewitz. The diagnosis and treatment of envenomation in South Africa. (Booklet)

3. Newlands, G. Review of the medically important spiders in Southern Africa. *SA Medical Journal*, Vol 49, May 1975, pp 823–826.

4. Newlands, G., Isaacson, C., Martindale, C. Loxoscelism in the Transvaal, South Africa. *Transactions of the Royal Society of Tropical Medicine and Hygiene*, Vol 76 No 5, 1982, pp 610–615.

5. Newlands, G., Martindale, C.B. Wandering spider bite – much ado about nothing. *SA Medical Journal*, Vol 60. 25 July 1981, pp 142–143.

6. Dippenaar-Schoeman, Anna S. Pamphlet no 146, *Farming in South Africa*. Printed in South Africa by the Government Printer, distributed by the Director, Division Agricultural Information, Pretoria. 1980.

7. Müller, G.J. Black and brown widow spider bites in South Africa. A series of 45 cases. *South African Medical Journal*, Vol 83, June 1993, pp 399–405.

8. Newlands, G., Martindale, C., Berson, S.D., Rippey, J.J. Cutaneous necrosis caused by the bite of Chiracanthium spiders. *SA Medical Journal*, Vol 57, 2 February 1980, pp 171–173.

9. Lotz, L.N. 1994. Revision of the genus *Latrodectus* (Araneinae: Theridiidae) in Africa. Navorsing van die Nasionale Museum, Bloemfontein 10(1):1–60.

10. Lotz, L. N. 1996. The genus *Cheiracanthium* (Araneinae: Clubionidae) in southern Africa. MSc thesis – University of the Orange Free State, Bloemfontein, 96pp.

11. Croeser, P.M.C. 1996. A revision of the African huntsman spider genus *Palystes* L. Koch, 1875 (Araneinae: Heteropodidae). *Annals of the Natal Museum* 37:1-122.

12. Croucamp, W. April 2000. Spider bites – diagnosis and management. *Journal of Continued Medical Education*. Vol 18(8): 670–678.

13. Filmer, M. R., Newlands, G. April 1994. Araneism in Africa south of the equator with key to clinical diagnosis. *Diseases of the Skin*. Vol 8(2): 4–10.

14. Maretic, Z. 1986. Spider Venoms and Their Effect. In Wolfgang Nentwig (ed) *Ecophysiology of Spiders*.

15. Newlands, G. Atkinson P. 20 Feb 1988. Review of southern African spiders of medical importance, with notes on signs and symptoms of envenomation. *South African Medical Journal*, Vol 73, pp 253-239.

16. Newlands, G., Atkinson, P. 20 Jan 1990. A Key for the clinical diagnosis of araneism in Africa south of the equator. *South African Medical Journal*, Vol 77, pp 96-97.

17. Newlands, G. Jul 1989 Arthropods that sting and bite man – their recognition and treatment of patient. *Journal of Continued Medical Education*. Vol 7(7): 773-784.

18. Muller, G. J. April 1999. Management of bites and stings: controversial aspects. Abstract of the 6th African Arachnological Colloquium. *African Arachnological Society Newsletter* 12.

19. Newlands, G. 1986. Necrotic Arachnidism in Southern Africa. PhD thesis – University of Witwatersrand, Johannesburg.